

جربا -

د. منان صهي
0597627168

Anatomy and Physiology of Heart & Lungs

Heart

The heart consists of cardiac muscle (myocardium). Weigh around 300mg and rest upon diaphragm. About $\frac{2}{3}$ rd of heart lies on the left side of the body's midline. Apex is directed anteriorly, inferiorly and to the left. Pericardium surrounds and protects the heart. Its confines the heart in the mediastinum. The heart pumps continuously, without resting and without becoming fatigued. Its function is to pump blood to the lungs and around the body. The heart is one of the key organs in the Circulatory System.

كلام
ع

Chambers:


The heart consists of four chambers and is divided into left and right by a wall of muscle called the septum.

The right side of the heart consists of an atrium which receives blood returning from the body, and the right ventricle, which then pumps blood out to the lungs, via the pulmonary artery.

SVC
IVC
في الوريد السطح

The left side again contains an atrium and a ventricle. The left atrium receives the oxygenated blood returning from the lungs and the ventricle then pumps this blood around the body.

Due to the distance which the blood being pumped from the left ventricle has to travel, a more forceful contraction is required. For this reason the muscular wall of the left side is thicker than that of the right side.



The atria and ventricles are separated by valves known as Atrioventricular, or AV valves. The purpose of these valves is to prevent blood from flowing in the wrong direction. Following the movement of blood from the atrium, into the ventricle, the AV valve snaps shut which causes the first heart sound of the heart beat (often described "lub dub", with the closing of the AV valves being the "lub"). Mitral Valve is on the left side.

closure of AV valve → 1st heart sound → lub

The "dub" sound is caused by the closing of two other valves, known as the Semilunar or SL valves. These are located between each ventricle and the artery leaving the heart, and again prevent the blood flowing backwards. Left side Aortic valve and on right side is Pulmonary valve.

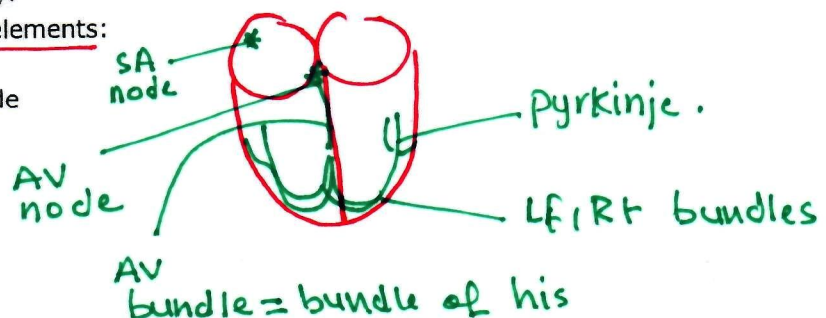
closure of semilunar valve → 2nd heart sound → dub.

Cardiac Conduction System:

the heart is able to create it's own electrical impulses and control the route the impulses take via a specialised conduction pathway.

This pathway is made up of 5 elements:

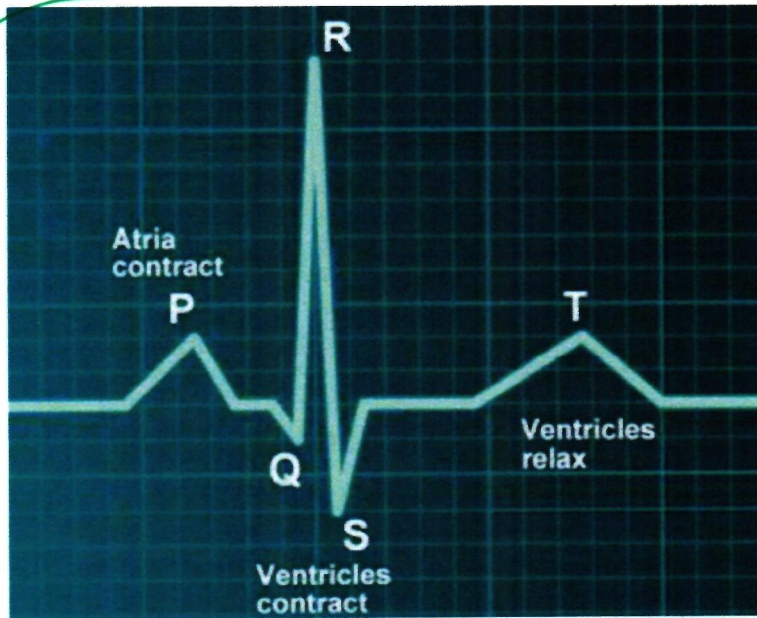
1. The sino-atrial (SA) node



2. The atrio-ventricular (AV) node
3. The bundle of His
4. The left and right bundle branches
5. The Purkinje fibres

The heart beat is caused by impulses arising from two specialised groups of cells within the heart muscle. The Sino-Atrial (SA) node, situated in the wall of the right atrium initiates the beat, and the Atrioventricular (AV) node which is positioned between the ventricles and continues to distribute the wave of impulses.

Heart Beat: Cardiac Systole describes the period at which the heart contracts and cardiac diastole describes the period of relaxation, between beats. They can however be further divided into diastole and systole of the atria and ventricles.



الدم يمر من الأوردة
إلى الأذينين
فتردد الصغرة
كهما ضغط
الضامس (AV)
ليجد الدم
إلى البطينين

- **TP Interval (Ventricular Diastole)** - Atria and ventricles are relaxed, blood is flowing into the atria from the veins. As the atrial pressure increases above that of the ventricle, the AV valves open, allowing blood to flow into the ventricle
- **P Wave (Atrial Systole)** - The SA node fires and the atria contract causing atrial systole which forces all blood into the ventricles, emptying the atria.
- **QR Interval (End of Ventricular Diastole)** - The AV valves remain open as all remaining blood is squeezed into the ventricles. The electrical impulse from the SA node reaches the

ببداية ان
R peak is the end of diastole and beginning of systole.

الأذينين ينفذ الدم من الأذين إلى البطين

موسم

AV node which spreads the signal throughout the walls of the ventricles via specialised cells called bundles of His and Purkinje fibres. The R peak is the end of ventricular diastole and the start of systole.

أهميته

Isovolumetric Contraction

→ **RS Interval (Ventricular Systole)** - As the blood is now all within the ventricles and so pressure is higher here than in the atria, the AV valves close. The ventricles start to contract although pressure is not yet high enough to open the SL valves

البطين يبدأ انقباضه ويغلق AV ويغلق SL بآنية بامره

لوا ترفع الضغط في البطين يفتح ال SL ويطبع الدم للأورطين

• **ST Segment (Ventricular Systole)** - Pressure increases until it equals Aortic pressure, when the SL valves open. The blood is ejected into the Aorta (and pulmonary artery) as the ventricles contract. At this time the atria are in diastole and filling with blood returning from the veins.

• **T Wave (Ventricular Diastole)** - Ventricles relax, the ventricular pressure is once again less than the aortic pressure and so the SL valves close. The cycle continues.

Cardiac volumes:

نيزد الضغط

Cardiac Volumes are the amount of blood moved by the heart at any time:

Stroke Volume (SV): This is the amount of blood pumped from the heart, each time the heart contracts. At rest this is between 70-100ml, during exercise the figure increases to 113-179ml. The fitter an individual is, the higher their stroke volume.

Cardiac Output (CO): The amount of blood ejected from the heart in the space of a minute. This can be calculated by multiplying the stroke volume and the heart rate (beats per minute). This can range from 5,000ml at rest to 35,000ml during maximal exercise.

End Diastolic Volume (EDV): The amount of blood within the left ventricle prior to the contraction (systolic) phase of a heart beat.

End Systolic Volume (ESV): The volume of blood remaining in the ventricle after contraction. The stroke volume is equal to EDV-ESV

Coronary circulation: coronary arteries arises from ascending aorta and branches into right and left coronary arteries. Blood is filled during the diastole in these coronary arteries.

Nervous supply: Vagus nerve.

Lungs

الدم في البطين قبل الانقباض
حجم الدم الباقي في البطين بعد الانقباض
السريري القاصية طاعة من ال ascending aorta.

The respiratory system consists of nose, pharynx, larynx, trachea, bronchi, alveoli and finally Lungs.

The mammalian lungs are designed to optimize exposure of blood to oxygen. The normal human lungs weigh about 1 kg, of which 40% to 50% is blood. These lungs contain about 2.5 L of air at end expiration and 6 L of air at full inflation.

The average human respiratory rate is 30-60 breaths per minute at birth, decreasing to 12-20 breaths per minute in adults.

RR

EDV-ESV

كمية الدم التي تطلع من القلب في الدورة العادية

كمية الدم التي تطلع من القلب في الدورة الواحدة

Trachea:

12 cm long, 2.5 cm in diameter, located anterior to esophagus and extends from larynx to 5th thoracic vertebra and called carina (triggering cough reflex) where it divides into right and left primary bronchi.

Supported by 16 to 20 C shaped ring of hyaline cartilage.

Each lung has an apex, base, 3 borders and two surfaces,

Apex: slightly superior to the clavical.

Base: broad concave base resting on diaphragm

Surfaces: costal and mediastinal.

Borders: inferior, posterior and anterior.

Lobes & Fissures:

- Right: three lobes (superior, middle & inferior) & two fissures oblique and horizontal and
- Left: two lobes (superior and inferior) & one oblique fissure.

Hilum: it constitute root of the lung, through which bronchus, blood vessels and nerves passes.

Mucus is secreted onto the bronchial surfaces by sub mucosal glands and by goblet cells.

Cilia aid in the transport of mucus and which is largely responsible for removing foreign material.

Alveoli begin to appear in the walls of the 17th generation of bronchioles, which are therefore referred to as respiratory bronchioles. By the 20th generation of airways, the entire wall of the airway is composed of alveoli, and these structures are referred to as alveolar ducts. Alveolar ducts end at about the 23rd generation in blind sacs, which are lined with alveoli and are referred to as alveolar sacs. There are approximately 300 million alveoli within the lungs and these provide a surface area of gas exchange.

Pleura: 23rd → alveoli

- 17th → respiratory bronchides.
- 20th → alveolar ducts

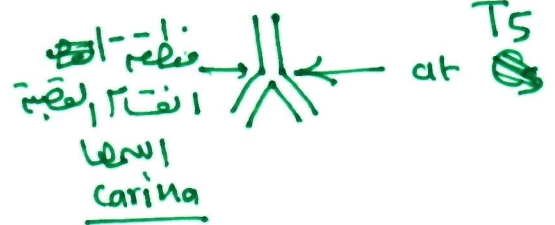
Covering of the lungs, two types: visceral layer covering the lungs is continuous with the "parietal" layer that covers the inner surface of the chest cavity. These two layers of pleura are separated by a thin layer of fluid, which amounts to less than 10 mL in the normal adult lungs.

Mechanics of Breathing/ Pulmonary Mechanics:

During inhalation, active contraction of the diaphragm and external intercostal muscles of the ribcage draw air into the lungs.

Although inhalation requires active muscle contraction, exhalation is normally a passive process and is dependent on the elasticity of the pulmonary tissues.

Physiology of Gas Exchange: Each alveolus is very closely associated with a network of capillaries containing deoxygenated blood from the pulmonary artery. The capillary and alveolar



الزئبق ليس
أبني

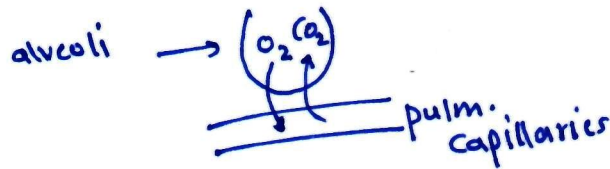
3 حواف
2 سطح

✓ الحجاب
✓ الأهداب
✓ الحويصلات

visceral cover the organ.
Parietal line the chest

diaphragm relax → elevate →
Size ↓ → volume ↓ Pressure ↑
volume → air out

↑
↓
air in



walls are very thin, allowing rapid exchange of gases by passive diffusion along concentration gradients.

CO₂ moves into the alveolus as the concentration is much lower in the alveolus than in the blood, and O₂ moves out of the alveolus as the continuous flow of blood through the capillaries prevents saturation of the blood with O₂ and allows maximal transfer across the membrane.

Control of respirations:

- ✓ 1. Inspiratory center
- ✓ 2. Expiratory center
- ✓ 3. Pneumotaxic center
- ✓ 4. Apneustic center

First two centers are present on medulla oblongata whereas last two centers on the Pons region of the brain.

Volumes and capacity:

The tidal volume (TV), about 500 mL, is the amount of air inspired during normal, relaxed breathing.

The inspiratory reserve volume (IRV), about 3,100 mL, is the additional air that can be forcibly inhaled after the inspiration of a normal tidal volume.

The expiratory reserve volume (ERV), about 1,200 mL, is the additional air that can be forcibly exhaled after the expiration of a normal tidal volume.

Residual volume (RV), about 1,200 mL, is the volume of air still remaining in the lungs after the expiratory reserve volume is exhaled.

The total lung capacity (TLC), about 6,000 mL, is the maximum amount of air that can fill the lungs ($TLC = TV + IRV + ERV + RV$).

The vital capacity (VC), about 4,800 mL, is the total amount of air that can be expired after fully inhaling ($VC = TV + IRV + ERV =$ approximately 80 percent TLC). The value varies according to age and body size.

The inspiratory capacity (IC), about 3,600 mL, is the maximum amount of air that can be inspired ($IC = TV + IRV$).

The functional residual capacity (FRC), about 2,400 mL, is the amount of air remaining in the lungs after a normal expiration ($FRC = RV + ERV$).

كمية الهواء الباقى في الرئة بعد الزفير الطبيعي

كمية الهواء المتبقية في الرئة بعد الزفير

كمية الهواء التي تتدفق في الرئتين وتطوع الزفير والتغذية

كمية الهواء الإضافية في الرئة

كمية الهواء المتبقية في الرئة بعد الزفير

أقصى كمية هواء يمكن تبص الرئة

كمية الهواء التي يمكن تطوع الرئة بأقصى زفير

أقصى كمية هواء يمكن استنشاق